

A Study of Anatomical Variations in the Arteries Supplying Gut Derivatives

Deepa G.*, Shivakumar G.L.**

Abstract

Anatomical variations in the branching pattern and distribution of the arteries supplying gut derivatives is very important especially for surgeons undertaking surgeries in the abdominal region. Anatomical variations contribute to the misinterpretation and leads to major postoperative complications. The present study was carried out in 32 adult cadavers (5 females and 27 male cadavers) which were used during routine dissection for undergraduate medical students. The course and branches of all the ventral branches of aorta was traced. Any arterial variation was observed and recorded. Anatomical variations related to the trifurcation of coeliac trunk, origin of the inferior phrenic artery, origin of the left gastric artery, origin of the accessory hepatic artery and the origin of the accessory right colic artery were noted and documented. In two cases, left colic artery was absent and inferior mesenteric artery gave rise to 3-4 sigmoid branches. The present study highlights on the importance of arterial variations in the abdomen which should not be ignored. Hence, the accurate knowledge of such variations is important in carrying out surgical procedures in the abdomen safely and also in the interpretation of angiographic reports.

Keywords: Arteries; Anatomic variation; Abdomen; Aorta; Cadaver.

Introduction

Abdominal aorta begins at the median, aortic hiatus of the diaphragm, anterior to inferior border of the 12th thoracic vertebra and the thoracolumbar intervertebral disc.[1] The major branches of abdominal aorta supply nearly all the organs in the abdominal cavity. The three ventral branches supply all the gut derivatives. The coeliac trunk which is the first ventral branch of abdominal aorta supplies the foregut derivatives. The trunk divides into the left gastric artery, the common hepatic artery and the splenic arteries. This trifurcation was first described by Haller in 1756. This 'Tripus Halleri' was and is still being considered to be the normal appearance of the

coeliac trunk.[2] Superior mesenteric artery supplies the mid gut[3] which include the portion of digestive tract extending from the duodenum at the opening of the bile duct to the junction between the right two third and left one third of the transverse colon.[4] Inferior mesenteric artery is usually smaller in caliber than the superior mesenteric artery which arises at about the level of L3, 3 to 4 cm above the aortic bifurcation and supplies the left one third of transverse colon, the entire descending and sigmoid colon, the rectum and the upper part of the anal canal up to the pectinate line.[1] Anatomical variations in the branching pattern and distribution of these arteries is very important especially for surgeons undertaking surgeries in the abdominal region.

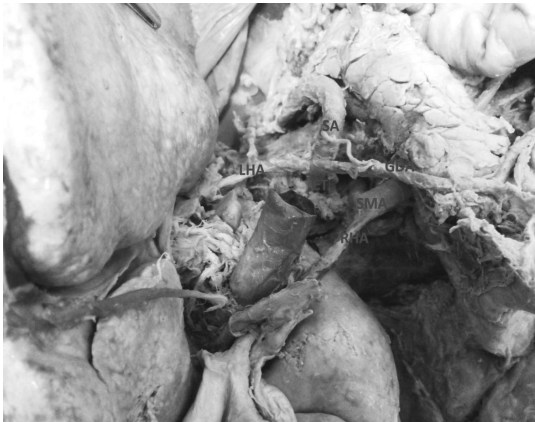Arterial variations in the ventral branches of abdominal aorta have been described by many authors. Anatomical variations in the coeliac trunk were first classified by Adachi in 1928, based on 252 dissections of Japanese cadavers, where 6 types of divisions of the coeliac trunk and superior mesenteric artery

Author's Affiliation: *Assistant Professor, **Professor, Department of Anatomy, Navodaya Medical College, Raichur Karnataka-584103, India.

Reprint's Request: Dr. Deepa G., Assistant Professor, Department of Anatomy, Navodaya Medical College, Raichur, Karnataka-584103, India.

E-mail: drdeepagadwal@gmail.com

Figure 1: Showing Coeliac Trunk Dividing into Left Hepatic Artery, Splenic Artery and Gastroduodenal Artery. Right Hepatic Artery was Observed to Be Arising from Superior Mesenteric Artery. Lha: Left Hepatic Artery. Ct: Coeliac Trunk. Sa: Splenic Artery. Gda: Gastroduodenal Artery. Sma: Superior Mesenteric Artery. Rha: Right Hepatic Artery.



were described.[5] Variations in the branching pattern of superior mesenteric artery is also been observed. In about 50% of cases, the marginal artery which is the result of anastomosis of the branches of superior mesenteric artery and inferior mesenteric artery may be discontinuous because of the failure in the anastomosis between the left and right colic arteries.[6] There have been reports of cases where the right and middle colic

Figure 2: Showing Inferior Phrenic Artery Arising from Left Gastric Artery. LGA: Left Gastric Artery. IPA: Inferior Phrenic Artery.

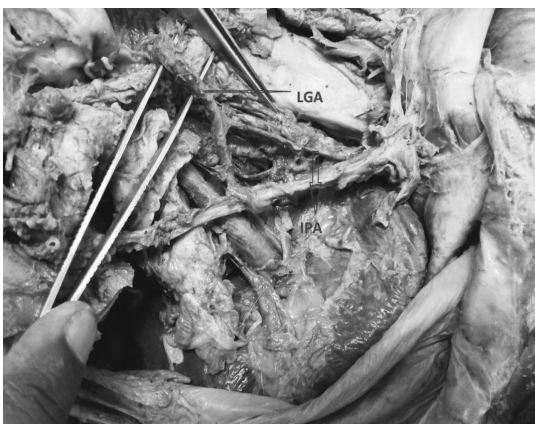
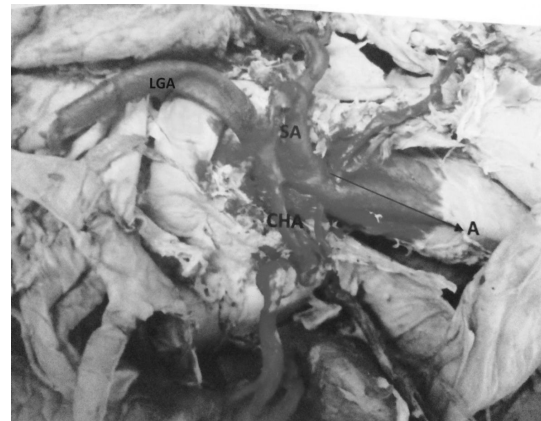

Figure 3: Showing Left Gastric Artery Arising from Abdominal aorta. Coeliac Trunk is Observed to Be Bifurcating into Splenic Artery and Common Hepatic Artery. A: Aorta. SA: Splenic Artery. CHA: Common Hepatic Artery. LGA: Left Gastric Artery.



arteries were absent leaving the entire supply of the colon to the inferior mesenteric artery.[7] Anatomical variations contribute to the misinterpretation and leads to major postoperative complications.[8]

Hence, the proper knowledge on these variations is necessary in order to avoid surgical injury and help the surgeons to minimize the aforementioned complications related to abdominal surgery and also to avoid improper imaging during surgery.

Figure 4: Showing Accessory Hepatic Artery Arising from Superior Mesenteric Artery. SMA: Superior Mesenteric Artery. Ac. HA: Accessory Hepatic Artery.

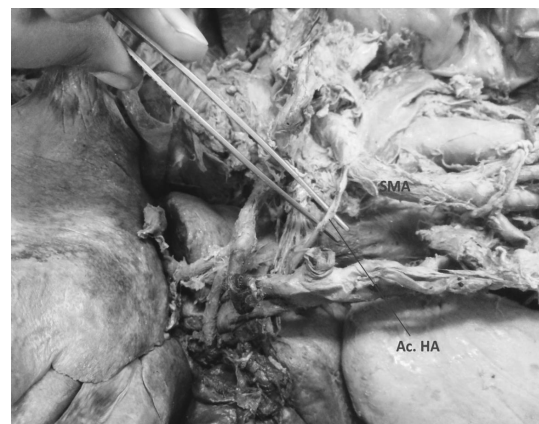
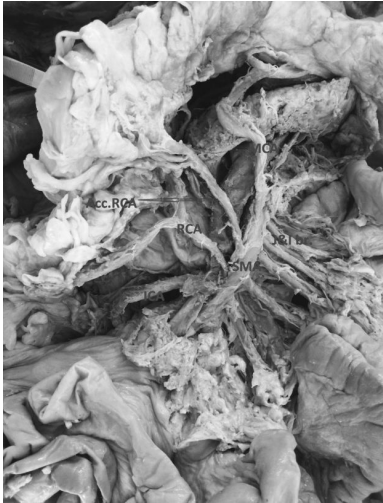

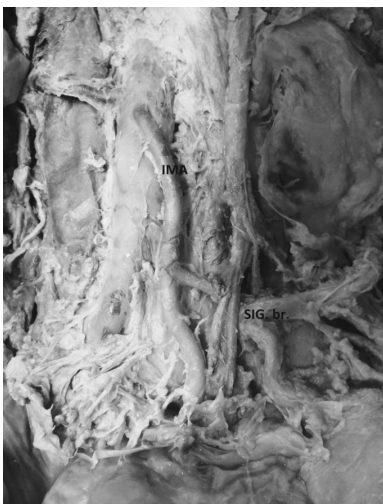Figure 5: Showing Accessory Right Colic Artery Arising from Superior Mesenteric Artery. SMA: Superior Mesenteric Artery. MCA: Middle Colic Artery. RCA: Right Colic Artery. ICA: Iliocolic Artery. Acc.RCA: Accessory Right Colic Artery. J&I br.: Jejunal & Iliac branches.



Materials and Methods

The present study was carried out in 32 adult cadavers (5 females and 27 male cadavers) which were used during routine dissection for undergraduate medical students in Department of Anatomy, Navodaya Medical College, Raichur. Anterior abdominal

Figure 6: Showing Absence of Left Colic Artery and Inferior Mesenteric Artery Giving Arise to only Sigmoidal Branches



wall was opened, and peritoneum and viscera were carefully separated. The course and branches of all the ventral branches of aorta was traced. Any arterial variation was observed and recorded.

Results

The following arterial variations were observed:

1. In one case, the normal trifurcation of coeliac trunk was not seen. Instead coeliac trunk divided into splenic artery, left hepatic artery and gastroduodenal artery. The left gastric artery was seen to be arising from left hepatic artery and right gastric artery originated from gastroduodenal artery. Right hepatic artery was observed to be arising from superior mesenteric artery. (Fig 1)
2. In two cases, the inferior phrenic artery was observed to be arising from left gastric artery instead of abdominal aorta.(Fig 2)
3. In one case, left gastric artery originated from directly from abdominal aorta. The coeliac trunk bifurcated into splenic artery and common hepatic artery. (Fig 3)
4. In three cases, accessory hepatic artery was noticed to be arising from superior mesenteric artery. (Fig 4)
5. In one case, superior mesenteric artery gave origin to accessory right colic artery. (Fig 5)
6. In two cases, left colic artery was absent and inferior mesenteric artery gave rise to 3-4 sigmoid branches. (Fig 6)

Discussion

The careful identification of anatomical vascular variations is very important and is of great importance for surgeons. Angiography is not routinely recommended, but it should

be mandatory when complex surgeries are planned.[9] Reported variations in the branching pattern of the coeliac trunk include absence of the trunk[10], presence of collateral vessels[11] and bifurcation of the coeliac trunk.[12] Such variations in the pattern of branching of the coeliac trunk may predispose to iatrogenic injury during surgical procedures such as total pancreatectomy[13] and resection of tumours of head of pancreas.[14] Knowledge of this variable anatomy may be useful in planning and executing radiological interventions such as celiacography[15], chemoembolization of hepatic tumours.[16]

The embryological basis related to these variations was made by Tandler and Morita. Tandler provided an embryological explanation for the variations in the coeliac trunk and the superior mesenteric artery in 1904. The ventral branches develop initially from the abdominal aorta as paired vessels, which then coalesce in the median line to form the four roots for the gut. The four roots are connected by a ventral longitudinal anastomosis.[17,18] Normally, the first root forms the left gastric artery, the second root forms the splenic artery and third root forms the common hepatic artery. The first three roots coalesce by the longitudinal anastomotic trunk to form the coeliac trunk. Superior mesenteric artery develops from the fourth root, which migrates caudally with the ventral migration of the gut.[19,20] According to Morita, the anomalous ramification of the coeliac trunk and superior mesenteric artery are due to the primitive ventral splanchnic arteries and their longitudinal anastomosis.[18,21]

Various studies were carried out regarding arterial variations. An angiographic study by Kostelic *et al* reports the prevalence of an accessory hepatic artery as 33%.[22]. Lippert and Pabst reported that they determined accessory left hepatic artery in 11% of cases, with varying origins, more often from the left gastric artery or the coeliac trunk.[23] Molmenti *et al* reported that the presence of replaced right hepatic artery in 15-20% and accessory left hepatic artery in 35% of

cases.[24] Malnar *et al* reports that the coeliac trunk divides into the common hepatic artery and splenic artery, where left gastric artery originates separately, proximal to the bifurcation of the coeliac trunk in 72% of cases in their study on Croatian cadavers.[25] A similar case was observed in the present study. Judy J Moon *et al* reported right hepatic artery branching from superior mesenteric artery.[26] Similar case was also noticed in the present study. This anatomical variant must be identified prior to procedures such as laparoscopic cholecystectomy to prevent vascular or biliary damage.[27] Preoperative detection of an aberrant right hepatic artery in prospective transplant donors and recipients is essential for the proper management of living donor liver transplantation, as transplantation of the right lobe is heavily favored over the left, and the aberration affects the safety of both donor and recipient.[28]

Cavdar *et al* reported a case, in which the left inferior phrenic artery and left gastric artery arose from the long coeliac trunk (4.3 cm) via a common trunk[29] Piano *et al* stated that the right and left inferior phrenic artery occasionally originated as a common trunk from the aorta, coeliaco-mesenteric system or adrenorenal system.[30] He observed that inferior phrenic arteries were usually paired(left and right) and their origin were summarized as follows - a) the abdominal aorta itself (61.6%), b) ventro-visceral arteries (coeliaco-mesenteric system of aorta) including coeliac trunk (28.2%) and left gastric artery (2.9%), c) the latero-visceral arteries (adreno-renal system of the aorta) including the middle adrenal artery (2.9%), and renal artery(4.3%).

Vascular variations of superior mesenteric artery have been studied by many authors. Right gastroepiploic artery has been reported to arise from superior mesenteric artery.[31] In the present study superior mesenteric artery was observed to give rise to accessory right colic artery. Middle colic arteries have been found to originate from the coeliac trunk at a rate of 0.5 - 1%.[32,33] An anomalous middle

colic artery originating from the common hepatic artery has been reported by Wadwa *et al.*[34] Gracia-Ruiz *et al* reported the presence of double middle colic artery in their cadaveric study.[35]

The arterial variations in the abdomen are usually asymptomatic. But the complete knowledge about vascular variations is very important during planning major abdominal surgeries and imaging procedures. Variations in the coeliac trunk may become important in patients who undergo coeliacography for gastrointestinal bleeding and the coeliac trunk compression syndrome, prior to an operative procedure or trans catheter therapy and for chemoembolization of pancreatic and liver tumours.[36] During minimally invasive or complicated hepatobiliary surgery an understanding of arterial variants in the lesser omentum is necessary if serious problems are to be avoided.[9] The knowledge about the hepatic arterial variation is very important for surgical gastroenterologists and interventional radiologists for preoperative planning and intraoperative imaging during procedures like liver transplantation, cholecystectomy, gastrectomy, hiatal hernial repair, trans arterial chemotherapy and hepatic arteriography.[37]

Conclusion

The present study highlights on the importance of arterial variations in the abdomen which should not be ignored. Hence, the accurate knowledge of such variations is important in carrying out surgical procedures in the abdomen safely and also in the interpretation of angiographic reports.

References

1. Susan Standring. Posterior abdominal wall and retroperitoneum. Gray's Anatomy-The anatomical basis of clinical practice, 39th ed. Philadelphia: Elsevier Churchill Livingstone; 2005, 1118.

2. Hemanth K, Garg S, Yadav TD, Sahni D. The hepato-gastro-phrenic trunk and the hepato-spleno-mesenteric trunk: A rare anatomical variation. *Tropical Gastroenterology*. 2011; 32(1): 56 – 59.
3. Moore KL and Persuad TVN. Clinically Oriented Embryology. 4th Ed. New Delhi: Saunders–Elsevier; 2004.
4. Moore KL and Dalley AF. Clinically oriented Anatomy. 5th Ed. Baltimore: Williams and Wilkin; 2006.
5. Adachi B (Das Arterien system der Japaner). Vol 2. Verlag der Kaiserlich-Japanischen Universitat Zu Kyoto, 1928. Japanese.
6. Basmajian JV. Grant's Method of Anatomy, 10th Ed. Baltimore: William and Wilkins; 1980.
7. Ano zeng Oyono Igiri, *et al.* The pattern of Arrangements and Distributions of the Superior Mesenteric Artery in a Nigerian Population. *Int J Morphol*. 2010; 28(1): 33–36.
8. Hiatt J R, Gabby J, Busutil R W. Surgical Anatomy of the hepatic arteries in 1000 cases. *Ann Surg*. 1994; 220: 50-2.
9. Lippert H, Pasbst R. Arterial variations in man. Classification and frequency. JF Bergmann Verlag. *Munchen*. 1985; 34-35: 71-3.
10. Van Damme JP and Bonte J. The branches of the celiac trunk. *Acta Anat*. 1985; 122(2): 110-4.
11. Cavdar S, Gurbuz J, Zeybek A, Sehirli U, Abik I and Ozdogmus O. A variation of coeliac trunk. *Kaibogaku Zasshi*. 1998; 3(5): 505-8.
12. Ucerler H and Asli A. Multiplicity of the variations in the ventral branches of abdominal aorta. *Ital J Anat Embryol*. 2001; 111(1): 15-22.
13. Van Damme JP and Bonte J. Vascular anatomy in abdominal surgery. Stuttgart: Thieme; 1990, 27-86.
14. Lin J. Celiomesentric trunk demonstrated by 3 – dimensional contrast – enhanced magnetic resonance angiography. *Hepatobiliarypancreas Dis Int*. 2005; 4(3): 472-4.
15. Gluck E, Gerhardt P and Schroder J. Value of vascular morphology for the selection of catheters in selective coeliacography and mesentericography. *Rofo*. 1983; 138(6): 664-9.
16. Aigner KR and Gailhofer S. Celiac axis infusion and microembolization for advanced stage III/ IV pancreatic cancer – a phase II study on 265 cases. *Anticancer Res*. 2005; 25(6c): 4407-12.

17. Tandler J. Uber die varietaren der arteriacoelia cauderen Entwicklung. *Anat Hefte*. 1904; 25: 473-500 (In German).
18. Morita M. Reports and conception of 3 anomalous cases of the superior mesenteric arteries. *Igaku Kenkyu*. 1935; 9: 1993-2006.
19. Adachi B. Das Arterien system Der Japaner, Band II. Kyoto: verlag der keiserlich Japanischen Universitatzu Kyoto, Maruzen publishing co; 1928; 28, 38, 54. (In Japanese).
20. Shomura S, Emua S, *et al*. Anatomical study on the branches of coeliac trunk (IV) comparison of the findings with Aachi's classification. *Acta Anat Nippon*. 1991; 66: 452-61.
21. Limura A, Oguchi T, Shibata M, Takahashi T. An anomalous case of the hepatic artery arising from the superior mesenteric artery. *Okajimas Folia Anat Jpn*. 2007; 84(2): 61-66.
22. Lurie AS. The significance of the variant left accessory hepatic artery in surgery for proximal gastric cancer. *Arch Surg*. 1987; 122: 725-8.
23. Couinaud C. L artere hepatiche In: foie: Etudes Anatomiques et chirurgicales. Paris: Masson et cie; 1957; 146-86.
24. Molmenti EP, Pinto PA, Kiein J, Klein AS. Normal and variant arterial supply of the liver and gall bladder. *Pediatr Transplant*. 2003; 7: 80-82.
25. Malnar D, Klasan GS, Miletic D, *et al*. Properties of the CT - anatomical study. *Coll Anthropol*. 2010; 34: 917 -21.
26. Judy J Moon *et al*. Right hepatic artery branching off the superior mesenteric artery and its potential implications. *International J of Anatomical Variations*. 2009; 2: 143-145.
27. Nicholson T, Travis S, Ettles D, Dyst J, Sadman P, Wedgewood K, Roysten C. Hepatic artery angiography and embolization for hemobilia following laparoscopic cholecystectomy. *Cardiovascular Intervent Radiol*. 1999; 22: 20-24.
28. Orguc S, Tercan M, Bozoklar A, Akyildiz MET AL. Variations in hepatic veins: helical computerized tomography experience in 100 consecutive living donors with emphasis on right lobe. *Transplant Proc*. 2004; 38: 2727-2732.
29. Hollinshed WH. Anatomy for surgeons. Vol. 2 (The Thorax, Abdomen and Pelvis. The stomach, duodenum, pancreas and spleen), 2nd ed. New York: Harper and Row Publisher; 1961, 590.
30. Piano Dx, Ohtsuka A, Murakmi T. Typology of abdominal arteries, with special references to inferior phrenic arteries and their oesophageal branches. *Acta Med Okayama*. 1988; 52: 189-96.
31. Sakamoto H, *et al*. An anomalous right gastroepiploic artery arising from the superior mesenteric artery. *Surg Radiol Anat*. 1999; 21(4): 283-6.
32. Michels NA, *et al*. Variant blood supply to the descending colon, rectosigmoid and rectum based on 400 dissections. Its importance in regional dissections: a review of medical literature. *Dis Colon Rectum*. 1965; 8: 51- 278.
33. Amonoo kuofi HS, *et al*. Anomalous origin of colic arteries. *Clin Anat*. 1995; 8: 288-93.
34. Wadhwa S, Barua MP. Anomalous middle colic artery originating from common hepatic artery: a case report. *Clin Anat*. 2008; 21: 798-9.
35. Garcia-Ruiz A, Milsom JW, Ludwig KA, Marchesa P. Right colonic arterial anatomy. Implications for laparoscopic surgery. *Dis Colon Rectum*. 1996; 39: 906 - 11.
36. Antony Sylvan D'souza, *et al*. Anatomical variations in the branches of the coeliac trunk. *Journal of Clinical and Diagnostic Research*. 2012; 6(3): 333-335.
37. Narayanaperumal Mugunthan *et al*. Anatomical variations in the arterial supply of liver. *International J of Anatomical Variations*. 2012; 5: 107-109.